

The British University in Egypt

BUE Scholar

Dentistry

Health Sciences

Winter 10-2020

Oral conditions in hepatitis C virus-infected Egyptian patients: a case-control study

Asmaa Ras

asmaa.aboubakr@bue.edu.eg

Eman Khalil

The British University in Egypt, Eman.Khalil@bue.edu.eg

Follow this and additional works at: <https://buescholar.bue.edu.eg/dentistry>



Part of the [Dental Public Health and Education Commons](#), and the [Virus Diseases Commons](#)

Recommended Citation

Ras, Asmaa and Khalil, Eman, "Oral conditions in hepatitis C virus-infected Egyptian patients: a case-control study" (2020). *Dentistry*. 148.

<https://buescholar.bue.edu.eg/dentistry/148>

This Article is brought to you for free and open access by the Health Sciences at BUE Scholar. It has been accepted for inclusion in Dentistry by an authorized administrator of BUE Scholar. For more information, please contact bue.scholar@gmail.com.



ORAL CONDITIONS IN HEPATITIS C VIRUS-INFECTED EGYPTIAN PATIENTS: A CASE-CONTROL STUDY

Asmaa Abou-bakr* and Eman Khalil**

ABSTRACT

Introduction: One of the serious public health problems nowadays is the hepatitis C virus (HCV) infection. Hepatitis C virus infection morbidity is associated with a diversity of extrahepatic disorders counting the oral cavity. Some of the oral manifestations are oral diseases like lichen planus and xerostomia and side effects of the virus therapy. The aim of this study was to evaluate and compare the oral health status, of patients with and without virus C in a sample of the Egyptian population.

Methods: Data were collected from the Gastroenterology department at Benha University. The study was designed as a case-control study; 39 Egyptian hepatitis C patients (Cases) and 75 Egyptian non-hepatitis C patients (Control). Oral examinations were done according to the modified WHO oral health survey 2013 criteria.

Results: The prevalence of xerostomia was 69.2 % and 69.3% in cases and controls respectively, with no statistically significance difference between the two groups. Skin hyperpigmentation was 46.2%, 16% in cases, and control groups respectively with a statistically significant difference between the two groups. The least manifestation was lichen planus, recurrent aphthous ulcer (RAU), and candidal infection.

Conclusions: Many changes in the oral cavity were found higher at the control group as compared to the case group except for the skin hyperpigmentation that was higher among the hepatitis C patients. Our findings reinforce other regional studies with a bigger sample in hepatitis C patients.

KEYWORDS: Oral, conditions, hepatitis C.

* Demonstrator at department of Oral medicine and Periodontology, Faculty of Dentistry, British university, Cairo, Egypt. Master candidate at Department of Oral medicine, Faculty of Dentistry, Ain Shams University, Cairo, Egypt.

** Assistant professor of Oral Medicine and Periodontology department, Faculty of Dentistry, British University, Cairo, Egypt.

INTRODUCTION

Hepatitis C virus (HCV) infection is widespread with an estimated 3% of the infected world population. Acute infection is usually mild but chronicity develops in as many as 80% of patients, of whom at least 20% will eventually develop cirrhosis (*Vladimir, 2013*). Morbidity associated with HCV infection is due not only to the sequelae of chronic liver disease but also to a variety of extrahepatic manifestations (EHM) in 74% of all HCV-infected individuals. Some of the most frequently reported EHM of HCV infection involves the oral region predominantly or exclusively (*Roy and Bagg, 1999*).

In the past few years, important efforts have been done to increase awareness over the possible transmission methods and treatment possibilities, the hepatitis C virus (HCV) remains a significant health concern worldwide. Chronic inflammation of the liver could occur as a result of the untreated viral infection. Moreover, the pathological events that HCV infection triggers expand beyond the liver, a number of extrahepatic manifestations including oral lesions (*Hoofnagle, 2002*).

The impact of HCV infection on oral health has received different opinions over time, varying from clinical evidence to meta-analysis and a further wider approach on the subject (*Carrozzo, 2008*). Defiant oral health for the patients with HCV could be due to liver failure, an impaired immune system, or the low motivation of the infected patients to seek dental care (*Coates et al., 2002; Carrozzo et. 2001*).

Several studies address the significance of HCV infection on the oral cavity, highlighting both the dental pathological changes and other extrahepatic manifestations (EHMs) with oral implications (*Alavian et al., 2013*). Epidemiological studies of oral mucosal lesions (OML) are rare globally in comparison with studies on caries and periodontal diseases (*Petersen et al., 2005*).

In oral medicine, dermatologic diseases have got special attention as OML may be the primary

clinical feature or the only sign of various mucocutaneous diseases (*Budimir et al., 2008; Bork, 2009*). Focusing on patients referred to a dermatologic clinic, *Ramirez-Amador et al* reported a prevalence of 35% OML in subjects affected with mucocutaneous conditions. Pemphigus Vulgaris, lichen planus, candidiasis, and recurrent aphthous ulcers were the most frequently diagnosed conditions (*Ramirez-Amador et al., 2000*).

Lesions of the skin may appear as the primary or only expression of hepatitis C, early management and prevention of the life-threatening complications can be achieved if these lesions were carefully investigated (*Raafia et al., 2014*). Yet, there have been no studies focusing on the prevalence of a wide spectrum of different types of OML in patients with dermatologic diseases. This is worth mentioning as skin lesions are related to oral lesions strongly and by dentists could neglect it due to deficiency of information and/or inappropriate diagnosis (*Ergun et al., 2009*).

MATERIALS AND METHODS

A case-control study was conducted during a period of 3 months, from March 2019 to May 2019 with 39 Egyptian hepatitis C patients (Cases) and 75 Egyptian non-hepatitis C patients (Control) who were recruited from the Gastroenterology department, faculty of medicine, Benha University. Both genders with an age range from 30 to 60 years were selected for both groups. HCV patients on or with a history of antiviral treatment and those without a history of treatment were considered. Patients who were both hepatitis C and hepatitis B positive or had any other etiology for the liver disease were excluded from the study. Informed consent was signed by all the participants and individual patient's results have been kept confidential.

Detailed history, clinical examination including cutaneous system and relevant investigations were carried out. All the information was recorded and

the data were analyzed thereafter. The frequency of various mucocutaneous manifestations in hepatitis C patients was documented. Patients who met the eligibility criteria were subjected to comprehensive oral assessment using a designed chart adapted from the World Health Organization oral health assessment form for adults, 2013, and scored (*OHS WHO 2013*).

The oral cavity was examined in both groups to identify any possible lesions and xerostomia under artificial light, by retracting the lips and cheeks, using disposable retractors, in accordance with biohazard safety procedures (*Grossmann et al., 2009*). Diagnostic criteria for OML were based on Axell criteria and those defined in previous studies and reviews (*Axell, 1976; Kramer et al., 1980; Axell*

et al., 1996; Regezi et al., 2008). All lesions with the clinical features of oral lichen planus were biopsied to confirm the diagnosis and each individual who provided tissue for the biopsy signed the informed consent form. For those who did not provide tissue for the biopsy, verbal consent was noted before recruitment to the study. Patients were asked about symptoms of xerostomia by standard questions for assessing dry mouth: do you feel dryness in the mouth at any time? Do you wake at night with a feeling of dryness in the mouth? Do you often need to drink liquids? (*Castro et al., 2002; Navazesh and Kumar, 2008*).

RESULTS

As showed in table 1.

TABLE (1) Showing the frequency of the oral lesions among the cases (HCV+v) and the controls (HCV-ve).

		Cases (39n) HCV+	Controls (75n) HCV-	Test value*	P-value	Sig
Xerostomia	No	12(30.8%)	23(30.7%)	0.000	0.991	NS
	Yes	27(69.2%)	52(69.3%)			
Lichen planus	No	30(76.9%)	60(80.0%)	0.146	0.702	NS
	Yes	9(23.1%)	15(20.0%)			
Candida	No	37(94.9%)	70(93.3%)	0.105*	0.745	NS
	Yes	2(5.1%)	5(6.7%)			
RAU	No	33(84.6%)	63(84%)	0.007	0.932	NS
	Yes	6(15.4%)	12(16.0%)			
Skin hyperpigmentation	No	21(53.8%)	63(84.0%)	12.031*	0.001	S
	Yes	18(46.2%)	12(16.0%)			

*P-value>0.05:Non significant; P-value <0.05:Significant ; *:Chi-square test; °:Independent t-test*

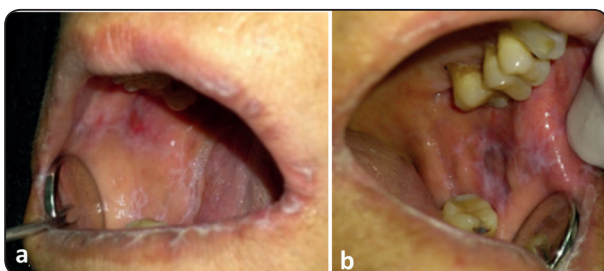


Fig. (1) a, b: showing atrophic&erosive lichen planus at the buccal mucosa bilaterally.

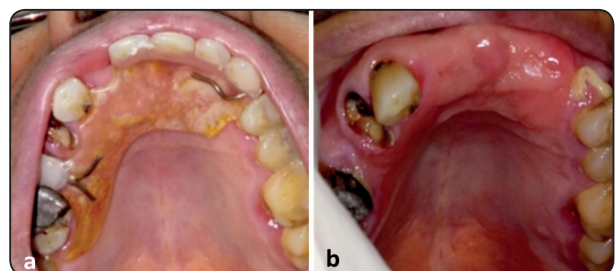


Fig. (2) a, b: showing denture stomatitis under removable partial denture at the hard palate.

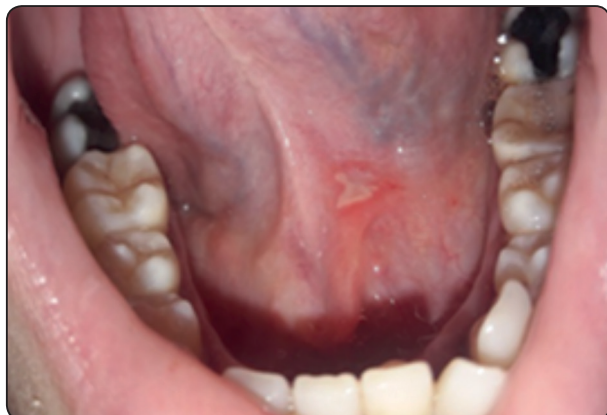

Fig. (3) RAU at the floor of the mouth.

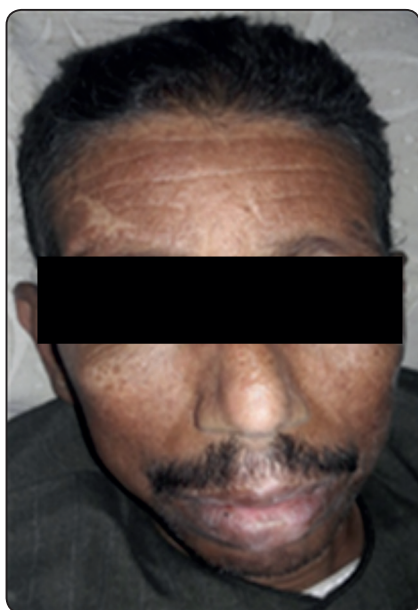

Fig. (4) Skin hyperpigmentation.

DISCUSSION

Skin hyperpigmentation was noticed in 46.2%, 16.0% in cases and control groups respectively with a statistically significant difference between two groups this finding is in accordance with *Raafia et al., 2014* with prevalence 34.1% in the hepatitis c patients and in contrast with previous studies which reported a much lower prevalence of 17% and 12.5% respectively in hepatitis c patients (*Cacoub et al., 2000; Paoletti et al., 2002*). This variation could be due to racial, genetic, and cultural differences in addition to variable exposure to risk factors.

Hyperpigmentation could be secondary to pegylated IFN therapy for chronic HCV infection has previously been reported in previous studies (*Gurguta et al., 2006; Sood et al., 2006*). This sequela may be caused by IFN-mediated up-regulation of melanocyte stimulating hormone receptors on melanocytes near sites of IFN injection and increased melanocyte secretion of α -melanocyte-stimulating hormone (*Torres et al., 2007*). Patients with darker skin types appear to be at increased risk for the development of IFN-induced hyperpigmentation (*Gurguta et al., 2006*).

Lichen Planus was 23.1%, 20% in cases and control groups respectively with no statistically significant difference between the two groups. Shulman et al., 2004 reported 25 % among the hepatitis C group of patients which is in accordance with our study. There is some evidence of an association between HCV and oral lichen planus (OLP); however, this varies by region. Epidemiological data suggest that LP may be significantly associated with HCV infection, mainly in Southern Europe and Japan (*Carrozzo, 2008*). Areas of burning or oral pain that increases with acidic or spicy foods are common symptoms in most of the patients. Symptoms are often irrespective of the clinical presentation (*ASHM, 2012*). A possible link between hepatitis viruses and LP has been suggested by the fact that LP has been frequently associated with chronic liver disease (CLD) in the Mediterranean but not in northern European patients (*Carrozzo, 2008*).

Xerostomia was found in the current study in 69.2%, 69.3% in cases and control groups respectively with no statistically significant difference between the two groups which was inconsistent with Australasian Society for HIV Medicine who reported 50% xerostomia in the hepatitis C infected subjects (*ASHM, 2012*). The incidence of dry mouth in patients with HCV infection has been increased, especially those

patients on antidepressant drugs, in addition to the known effects of HCV on salivary glands (*Carrozzo, 2008; Alavian et al., 2013*). Salivary depletion may result in dental caries, altered taste, burning sensation in the mouth, candidiasis, halitosis, difficulty chewing, swallowing and talking, and difficulty wearing dentures, dry mouth, and lips, sialadenitis (*Alavian et al., 2013*).

RAU was 15.4% and 16 % in cases and control groups respectively, with no statistically significant difference between the two groups. The frequency of recurrent aphthous stomatitis (RAS) has been recorded as lifetime prevalence, point prevalence, and a combination of both. Previous studies revealed a lower prevalence than our study with a percentage of 2.9%, 2%, and 0.8% reported by (*Axell and Shulman et al., 2004; Suliman et al., 2011*). A higher prevalence of 60% and 55% was reported in US female student nurses and professional school students respectively (*Jurge et al., 2006*). This could explain how RAS differs among the examined study groups. A number of factors have been attributed to the occurrence of this pathology, including immune dysfunction (*Regezi et al., 2008*).

Candidal infection was 5.1% and 6.7% in cases and control groups respectively, with no statistically significant difference between the two groups. However, candidiasis has been considered as one of most prevalent lesions associated with systemic disorders, with ranges varying from 5 to 92 % and this fact could be related to many factors such as the presence of *Candida* in the oral cavity in healthy conditions (*Cassone and Cauda, 2012; Ryder et al., 2012*) and the opportunistic nature of this yeast, being associated with severe immunosuppression, in special, the pseudomembranous type (*Ryder et al., 2012*). Therefore, presence of some oral conditions, such as candidiasis, should be some kind of awareness to the possible systemic conditions, in cooperation with physicians and dentists, it will lead to early diagnosis and treatment (*Gemaque et al., 2014*).

CONCLUSION

Patients with HCV can present a number of extrahepatic manifestations such as those in the oral cavity and this very important as chronic hepatitis C virus can remain asymptomatic for a long time. The dentist has an active role in detecting infection with hepatitis C, efforts should be made to clarify the possible relation between oral conditions and HCV infection. On the other hand, given the risks, the dental treatment of patients with known chronic HCV liver disease require special problems.

REFERENCES

1. Alavian SM, Mahboobi N, Mahboobi N and Karayianis P. Oral Conditions Associated with Hepatitis C Virus Infection. *Saudi J Gastroenterol.* 2013 Nov-Dec; 19(6): 245–251.
2. Australasian Society for HIV Medicine, Dental and orofacial health and hepatitis C. ASHM, 2012.
3. Axell T, Pindborg JJ, and Smith CJ, van der Waal I: Oral white lesions with special reference to precancerous and tobacco- related lesions: conclusions of an international symposium held in Uppsala, Sweden, May 18-21 1994. International Collaborative Group on Oral White Lesions. *J Oral Pathol Med* 1996, 25(2):49-54.
4. Axell T: A prevalence study of oral mucosal lesions in an adult Swedish population. *Odontol Revy Suppl* 1976, 36:1-103.
5. Bork K: Diseases of the Lips and Mouth. In Braun-Falco's *Dermatology*. 3 edition. Edited by: Burgdorf WHC, Plewig G, Wolff HH. Landthaler M: Springer; 2009:1081-1107.
6. Budimir J, Mihic LL, Situm M, Bulat V, Persic S, Tomljanovic-Veselski M: Oral lesions in patients with pemphigus vulgaris and bullous pemphigoid. *Acta Clin Croat* 2008, 47(1):13-18.
7. Cacoub P, Renou C, Rosenthal E et al. Extrahepatic manifestations associated with hepatitis C virus infection. *Medicine (Baltimore)*. 2000; 79:47-56.
8. Carrozzo M, "Oral health in patients with hepatitis C virus infection: an underestimated problem?" *Oral Diseases*, vol. 7, no. 5, pp. 267–270, 2001.
9. Carrozzo M. Oral diseases associated with hepatitis C virus infection. Part 1. sialadenitis and salivary glands lymphoma. *Oral Dis.* 2008 Mar; 14(2):123-130.

10. Carrozzo M. Oral diseases associated with hepatitis C virus infection. Part 2: lichen planus and other diseases. *Oral Dis.* 2008 Apr; 14(3):217228.
11. Cassone A and Cauda R, "Candida and candidiasis in HIV infected subjects. Where commensalism, opportunistic behavior and frank pathogenicity lose their borders," *AIDS*, vol. 26, no.12, pp.1457-1472, 2012.
12. Castro Ferrero M, Hermida Preto M, Barral Rodriguez S, Laredo Vazquez R, Castro Iglesias A, Diz Dios P. Whole stimulated salivary flow in patients with chronic hepatitis C virus infection. *J Oral Pathol Med*2002; 31: 11720.
13. Coates EA, Brennan D, Logan RM et al., "Hepatitis C infection and associated oral health problems," *Australian Dental Journal*, vol. 45, no. 2, pp. 108-114, 2000.
14. Ergun S, Ozel S, Koray M, Kurklu E, Ak G, Tanyeri H: Dentists' knowledge and opinions about oral mucosal lesions. *Int J Oral Maxillofac Surg* 2009, 38(12):1283-1288.
15. Gemaque K, Nascimento GG, Junqueira JC, Araújo VC, and Furuse C. Prevalence of Oral Lesions in Hospitalized Patients with Infectious Diseases in Northern Brazil. *Scientific World Journal* .Vol 2014, Article ID 586075, 5 pages.
16. Grossmann SM, Teixeira R, de Aguiar MC, de Moura MD, do Carmo MA. Oral mucosal conditions in chronic hepatitis C Brazilian patients: a cross-sectional study. *J Dent Public Health*2009; 69: 168-75.
17. Gurguta C, Kauer C, Bergholz U, Formann E, Steindl-Munda, Ferenci P. Tongue and skin hyperpigmentation during PEG-interferonalpha/ribavirin therapy in dark-skinned non-Caucasian patients with chronic hepatitis C. *Am J Gastroenterol* 2006;101:197-8.
18. Hoofnagle HJ, "Course and outcome of hepatitis C," *Hepatology*, vol. 36, no. 5, Supplement 1, pp. S21-S29, 2002.
19. Jurge S, Kuffer R, Scully C, Porter SR: Mucosal disease series. Number VI. Recurrent aphthous stomatitis. *Oral Dis* 2006, 12(1):1-21.
20. Kramer IR, Pindborg JJ, Bezroukov V, Infirri JS: Guide to epidemiology and diagnosis of oral mucosal diseases and conditions. World Health Organization. *Community Dent Oral Epidemiol* 1980, 8(1):1-26.
21. Nada M Suliman, Anne N Åstrøm, Raouf W Ali, Hussein Salman and Anne C Johannessen. Oral mucosal lesions in skin diseased patients attending a dermatologic clinic: a cross-sectional study in Sudan. *BMC Oral Health* 2011, 11:24.
22. Navazesh M, Kumar SK. Measuring salivary flow challenges and opportunities. *JADA*2008; 139: 35-40.
23. Paoletti V, Mammarella A, Basili S et al. Prevalence and clinical features of skin diseases in chronic HCV infection. A prospective study in 96 patients. *Panminerva Med.* 2002; 44:349-52.
24. Petersen PE, Bourgeois D, Ogawa H, Estupinan-Day S, Ndiaye C: The global burden of oral diseases and risks to oral health. *Bull World Health Organ* 2005, 83(9):661-669.
25. Raafia Ali, Muhammad Ashfaq, Mohammed Azam Bukhari, Atif Shahzad. Mucocutaneous manifestations in hepatitis C patients. *Journal of Pakistan Association of Dermatologists.* 2014; 24 (1):40-45.
26. Ramirez-Amador VA, Esquivel-Pedraza L, Orozco-Topete R: Frequency of oral conditions in a dermatology clinic. *Int J Dermatol* 2000, 39(7):501-505.
27. Regezi AJ, Sciubba JJ, Jordan RCK: Oral Pathology clinical pathologic correlations. Linda Duncan; 5 2008.
28. Roy K, Bagg J. Hepatitis C virus and oral disease: a critical review. *Oral Dis.* 1999 Oct; 5(4):270-277.
29. Ryder MI, Nittayananta W, Coogan M, Greenspan D, and Greenspan JS, "Periodontal disease in HIV/AIDS," *Periodontology*2000, vol.60, no.1, pp.78-97, 2012.
30. Shulman JD, Beach MM, and Rivera-Hidalgo F: The prevalence of oral mucosal lesions in U.S. adults: data from the Third National Health and Nutrition Examination Survey, 1988-1994. *J Am Dent Assoc* 2004, 135(9):1279-1286.
31. Sood A, Midha V, Bansal M, Goyal A, Sharma N. Lingual hyperpigmentation with pegylated interferon and ribavirin therapy in patients with chronic hepatitis C. *Indian J Gastroenterol* 2006;25:324.
32. Torres HA, Bull L, Arduino RC, Barnett BJ. Tongue hyperpigmentation in a caucasian patient coinfectd with HIV and hepatitis C during peginterferon alfa-2b and ribavirin therapy. *Am J Gastroenterol* 2007;102:1334-5.
33. Vladimir E. Panov. Oral Manifestations of Hepatitis C Virus. *J of IMAB.* 2013, vol. 19, issue 4.