

The British University in Egypt

**BUE Scholar**

---

Dentistry

Health Sciences

---

2021

## Assessment The Propolis Effect Versus Calcium Hydroxide Effect as Intracanal Medications on Post-Operative Pain in Necrotic Teeth

Engy M. Kataia  
engy.medhat@bue.edu.eg

Follow this and additional works at: <https://buescholar.bue.edu.eg/dentistry>



Part of the [Endodontics and Endodontology Commons](#)

---

### Recommended Citation

Kataia, Engy M., "Assessment The Propolis Effect Versus Calcium Hydroxide Effect as Intracanal Medications on Post-Operative Pain in Necrotic Teeth" (2021). *Dentistry*. 188.  
<https://buescholar.bue.edu.eg/dentistry/188>

This Article is brought to you for free and open access by the Health Sciences at BUE Scholar. It has been accepted for inclusion in Dentistry by an authorized administrator of BUE Scholar. For more information, please contact [bue.scholar@gmail.com](mailto:bue.scholar@gmail.com).



## Assessment The Propolis Effect Versus Calcium Hydroxide Effect as Intracanal Medications on Post-Operative Pain in Necrotic Teeth

Mohammed E. Rokaya<sup>1\*</sup>, Mahmoud M. Badr<sup>2</sup>, Engy M. Kataia<sup>3</sup>

Codex : 01/2021/10

Aadj@azhar.edu.eg

### KEYWORDS

*Propolis, Calcium hydroxide, intracanal medications, pain, necrotic teeth.*

### ABSTRACT

**Aim:** to evaluate the postoperative pain of using Propolis versus Calcium hydroxide as intracanal medications on post-operative pain in necrotic teeth. **Subjects and Methods:** 40 patients requiring endodontic treatment for single rooted teeth were enrolled in this analysis. The selected patients were separated into two groups with 20 patients each; Group I: Propolis paste. Group II: Ca (OH)<sub>2</sub> paste. The local anesthesia was administrated, and the working length determined by Root ZX apex locator, and then confirmed radiographically. The root canals were mechanically prepared in a crown-down approach using the “TF Adaptive” setting on Elements Motor. TF Adaptive Green ML1 file (Medium Large) and Yellow ML2 size 35 taper 4% until the file reaches wanted length. Intracanal medicaments of the two groups were placed inside the canals and left for a week. Then the obturation was done in the second visit. Postoperative pain was judged by visual analogue scale (VAS) after 24 hours, 48 hours and 72 hours. **Results:** The pain intensity showed that there was no statistically noteworthy difference concerning the two groups. **Conclusions:** Propolis is an effective and safe intracanal medication that can be used to reduce post-operative pain in necrotic teeth.

### INTRODUCTION

Pain and related suffering are globally relevant topics for health-care providers <sup>(1)</sup>, Pain of endodontic origin is widely feared by the public <sup>(2)</sup>, but only 17% of subjects experiencing root canal treatment described it as their most painful dental experience <sup>(3)</sup>. Root canal therapy lowers pain incidence although immediate post-treatment pain severity may sometimes exceed the pretreatment sternness levels. Current inflammatory processes or apical instrumentation especially with former peri radicular inflammation may cause this <sup>(4)</sup>.

Post-operative pain predominance at 24 hours was 40% and markedly decreased during the first 2 days after treatment, dropping to 10% or less after 7 days. Flare-up defined as a serious exacerbation of a pulpal or peri radicular pathosis with a subsequent development of pain

1. Department of Endodontics, Faculty of Dental Medicine, Al-Azhar University, Assuit, Egypt.
2. Department of Endodontics, Faculty of Oral and Dental Medicine, Future University, Egypt.
3. Department of Restorative and Dental Materials, National Research Centre, Egypt.

\* Corresponding Author e-mail:  
mrokaya@azhar.edu.eg

and swelling after the initiation or continuation of the root canal treatment. Pain usually starts within a few hours or days after root canal procedures and frequently requires unprepared spontaneous visits<sup>(5)</sup>.

An inter-appointment flare-up is more unusual. Studies have reported varying regularities of flare-ups, alternating between 2% and 15% <sup>(6)</sup>. Although all instrumentation procedures create apical extrusion of trash even when the preparation kept at the apical boundary, the difference lies in the ability of some techniques to extrude less remains than others do <sup>(7)</sup>.

Ca(OH)<sub>2</sub> is used worldwide as an intracanal medication due to its broad spectrum and long sustaining antimicrobial action and anti-inflammatory action <sup>(8)</sup>. Its antimicrobial effect is owed to its alkaline PH when it directly contacts the tissues<sup>(9)</sup>. The anti-inflammatory action is through its hydrolysis of lipopolysaccharides (LPS) and denaturing of endotoxins <sup>(10)</sup>.

Propolis is a natural wax-like beehive or flavonoid rich resinous product produced by bees as a defensive mechanism against infections. It has antibacterial, antifungal, anti-inflammatory properties and enhance healing <sup>(11-13)</sup>.

Therefore, the aim of this randomized clinical trial is to compare the effect of propolis versus Ca(OH)<sub>2</sub> as intracanal medications on postoperative pain.

## PATIENTS AND METHOD

An overall of 40 patients requiring endodontic treatment of both sexes with single rooted teeth. All the subjects were selected from the outpatient clinic of the Department of Endodontics, Faculty of Dentistry, Future University in the duration from June 2019 to January 2020. All the patient was agreed to be incorporated in this study by written agreement.

\* *Endo-ice Maquira, Brazil.*

## Diagnostic procedures

Diagnostic data (medical and dental) were collected by the investigator and confirmed for eligibility.

The identification of necrotic pulp with chronic periapical periodontitis was based on history taking and both clinical and radiographic examination.

**Personal history:** Including the patient's name, age, gender, address and phone number.

**Medical history:** Including any current or past medical condition, medication, or surgeries, in addition, any complication.

**Dental history:** Including past dental history and full history of the chief complain (intensity, nature, quality, onset, location, and duration, course, initiating and relieving factors).

## Clinical examination

Visual examination using mirror and probe to detect caries, restoration, swelling or sinus tract related to the offending tooth. Palpation and percussion tests were done to detect the periapical status.

### a) Subjective findings:

All patients incorporated in the trial had no pain pre-operatively.

### b) Objective findings:

## Thermal pulp testing:

Cold test was done using endo-ice spray which was done by applying cold-sprayed\* cotton on the tested tooth compared to the contralateral tooth and the duration of the cold test response was recorded. No pain after application was an indication of necrotic pulp. Hot test was also done by applying hot condenser on the tested tooth compared to the contralateral tooth and the response was recorded. No pain after application was an indication of necrotic pulp.



**Radiographic examination:**

This was performed with periapical film\* using bisecting angle technique to detect the number of roots and root canals and the status of periodontal ligament, lamina dura and periapical bone. Participants with periapical lesions presented as radiolucency or widening in the periodontal membrane space were incorporated in the study.

**Inclusion criteria:**

- Patients with age range 20 - 40 years.
- Medically-free of any systemic disease.
- Asymptomatic necrotic single-rooted single canal teeth:
  - 1) with or without chronic periradicular lesion.
  - 2) with complete root formation.
  - 3) without curvatures.
  - 4) without calcified root canals.
  - 5) without root caries.
  - 6) without internal or external root resorption.
  - 7) without anatomic abnormalities such as fusion.

**Exclusion criteria:**

- I. Pregnant females.
- II. Patients under antibiotic or analgesic administrations.
- III. Patients with facial swelling or acute infection or pain on percussion.
- IV. Teeth that are not indicated for endodontic treatment: bad oral hygiene, mobile or recessed.
- V. Previously endodontically treated teeth.
- VI. Teeth with sinus tract.

**Preparation of Propolis<sup>(14)</sup>:**

It was prepared in National Research Centre

1. 250g of crude propolis\*\* was macerated with 1 liter of 70% ethanol alcohol for 2 weeks in the dark at room temperature.
2. The aqueous ethanolic extract was filtered through Whatman filter paper\*\*\* no. 1.
3. The filtrate was evaporated with the rotary evaporator\*\*\*\* at 50°C.
4. As the resulted extract was viscous, it was manipulated using water and alcohol. Then the mixture was dried in oven under vacuum\* at 50°C until the required creamy consistency was reached.
5. The resulted mixture was 85% pure propolis and rendered by 15% radio-opaque by barium sulfate.

**Sequence of procedural steps:****At the first appointment:**

- The access cavity was done under rubber dam isolation using a sterile round bur and water as a coolant. Widening the canal orifices were done by One Flare™.
- The patency of the canals was done with hand K-files\*\*\* sizes #10.
- Working length was determined using an electronic apex locator\*\*\*\* and confirmed with intra-oral periapical radiograph to be 0.5-1 mm shorter than radiographic apex.

\* Vatech RVG Dental Imaging System Intraoral Digital X-Ray EZ SENSOR SIZE 1.5, Korea.

\*\* Propolis, Imtenan Corporate Headquarters is in Obour City, Egypt.

\*\*\* Whatman, GE Health care, US.

\*\*\*\* Heidolph rotary evaporator, Heidolph, Germany.

• Vaco Term, J.P Selecta, Spain.

•• Micro-mega, France.

••• K-file Hand files, Mani, Japan.

•••• Root ZX, J.Morita USA, Irvine, CA.

### TF Adaptive canal shaping technique:

- Use the “TF Adaptive” setting on Elements Motor.
- The pulp chamber was flooded with 5.25% NaOCl\*.
- Slowly advance the TF Adaptive Green ML1 file (Medium Large) size 25 taper 8%. The speed of rotation was 500 rpm and torque were 4 Ncm with a single controlled motion until the file engages dentin then completely withdraw the file from the canal (7).
- Wipe off the flutes. Deliver 5 ml of 5.25% NaOCl solution to the pulp chamber
- Steps 3 and 4 was repeated using the file ML1 until working length is achieved.
- Repeat steps 3 and 4 with the Yellow ML2 size 35 taper 4% until the file reaches working length.
- The canals were thoroughly irrigated using 2ml of 2.6% sodium hypochlorite and 17 % EDTA solution between every successive file. With the aid of a 27-gauge needle\*\* at a depth of 2-3mm from the working length. Finally, 5ml of 2.6% sodium hypochlorite, 5 ml of 17% EDTA solution, and 10 ml of distilled water were used as a flush of the canals.
- Paper Points were used to dry the canals.

### Placing the medicaments:

- **Group I propolis paste (20 patients):** was subjected to propolis paste, as intracanal medicament for one week after the cleaning and shaping. Propolis paste was injected inside the canal using a long disposable tip\*\*\* and checked with periapical radiograph.
- **Group II Ca(OH)<sub>2</sub> paste (20 patients):** was subjected to Ca(OH)<sub>2</sub>, as intracanal medicament for the full working length of the canal for one week after the cleaning and shaping.

\* Sodium hypochlorite (Clorex) Household Cleaning Products, Company of Egypt Ltd, Egypt.

\*\* NaviTip, ULTRADENT, USA.

\*\*\* METABIOMED.CO.,LTD, Korea

\*\*\*\* META Paste, METABIOMED.CO.,LTD, Korea.

Ca(OH)<sub>2</sub>\*\*\*\* META Paste was in the form of a ready-made paste and injected inside the canal using its long disposable tip.

- Resin-modified glass ionomer was used as a temporary restoration to ensure proper sealing with no leakage of any oral fluids inside the root canal which may disturb the action of the intra-canal medication.
- Pain was assessed by giving the patient the numerical pain rating scale (NRS) (Figure 1) to assess his/her pain at 24, 48 and 72 hours after the first visit. This scale is consisted of a line oriented horizontally. The number “0” is located on the left side of the scale, the number “10” is located on the right side of the scale. The patient is asked to rate his or her pain intensity on a balance of 0 to 10, with 0 indicating no pain and 10 indicating severe pain.
- Patients were phone-called at 24, 48 and 72 hours after the first visit to make sure that the pain had been listed on the NRS.

Fig. (1) A photograph showing the numerical pain rating scale (NRS).



### *At the second appointment (After 1 week):*

- Pain was assessed by the NRS before the beginning of obturation.
- Rubber dam application and removal of glass ionomer filling using a sterile round bur.
- Removal of the intracanal medicament using NaOCl irrigation and master apical file till reaching full working length with lateral strokes on the canal walls to ensure complete removal of the intracanal medicament.
- Final irrigation 5ml of 2.5% NaOCl followed by 5ml of 17% EDTA solution with saline in between and the canal was dried using sterile paper points.
- the obturation was done by lateral condensation technique with gutta pearch size 35 taper 6%, and AH plus sealer in the same visit, and using gutta pearch size 25 taper 2% as auxiliary cones with spreader size 25.
- The coronal final restoration was done by Filtek™ Z250 Light cured composite.
- Post-operative pain as the primary outcome was measured by a numerical pain rating scale (NRS), where the level of pain will be recorded as follows: 0 reading represents “no pain” ; 1- 3 reading represents “mild pain” ; 4- 6 reading represents “moderate pain” and 7- 10 reading represents “severe pain”
- Postoperative pain was filled by the patients after the first appointment at these specific times: 24, 48 and 72 hours and one week after the first appointment (at the clinic).

### **Statistical analysis:**

Arithmetic analysis was performed using a commercially available software program (SPSS 19; SPSS, Chicago, IL, USA). Significance of the difference between ages of both groups was evaluated using unpaired t test.

Pain score revealed a non-parametric distribution and was compared between both groups using Mann-Whitney U test and within the same group (effect of time) using Friedman test.

Chi square test was used to compare gender distribution, qualitative pain score and flare-up. The level of significance was set at  $P < 0.05$ .

## **RESULTS**

### **Pain incidence in different pain categories:**

The pain incidence at different pain categories (no pain, mild pain, moderate pain and severe pain) for the two groups (**Group I propolis paste**, **Group II Ca(OH)<sub>2</sub> paste**) presented in table (1) and illustrated in figure (2).

**Table (1)** Shows the pain incidence at different pain categories.

Period	Pain category	Group I propolis paste	Group II Ca(OH) <sub>2</sub> paste	P-Value
		[n (%)]	[n (%)]	
24 hours	No pain	8(40%)	9(45%)	0.891 <sup>ns</sup>
	Mild pain	6(30%)	5(25%)	
	Moderate	5(25%)	5(25%)	
	Sever pain	1(5%)	1(5%)	
48 hours	No pain	11((55%)	12(60%)	0.732 <sup>ns</sup>
	Mild pain	6(30%)	4(20%)	
	Moderate	2(10%)	4(20%)	
	Sever pain	1(5%)	0(0%)	
72 hours	No pain	15(75%)	17(85%)	0.642 <sup>ns</sup>
	Mild pain	4(20%)	3(15%)	
	Moderate	1(5%)	1(5%)	
	Sever pain	0(0%)	0(0%)	
P-Value		< 0.001*	< 0.001*	

\* Significant difference. ns; non-significant.

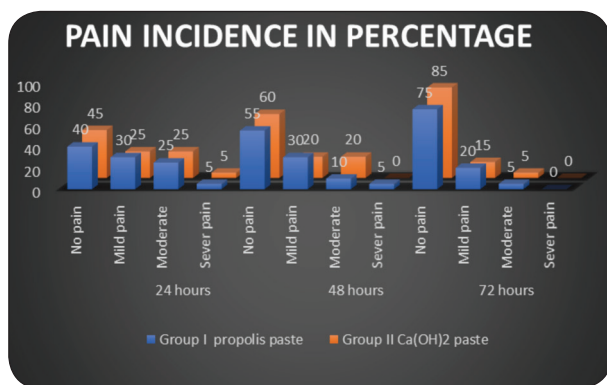


Fig. (2): Column chart showing the pain incidence at different pain categories

#### After 24 hours:

There was no arithmetic important difference between the two groups ( $P=0.891$ ). In **Group I**; 40% had no pain, 30% had mild pain, 25% had moderate pain and 5% had severe pain. For **Group II**; 45% had no pain, 25% had mild pain, 25% had moderate pain and 5% had severe pain.

#### After 48 hours:

There was no arithmetic important difference between the two groups ( $P=0.732$ ). In **Group I**; 55% had no pain, 30% had mild pain, 10% had moderate pain and 5% had severe pain. However, in **Group II**; 60% had no pain, 20% had mild pain, 20% had moderate pain, and 5% had severe pain.

#### After 72 hours:

There was no arithmetic important difference between the two groups ( $P=0.642$ ). In **Group I**; 75% of cases had no pain, 20% had mild pain, 5% had moderate pain, and 0% had severe pain. However, in **Group II**; 85% of cases had no pain, 15% had mild pain, 5% had moderate pain, and 0% had severe pain.

#### Changes by time in VAS scales of Group I:

A arithmetic important decrease in pain levels was recorded when comparing pain levels at 24 hours showed mean VAS score 12, while at 48 hours recorded 9, and 72 hours recorded 5 ( $p<0.001$ ).

#### Changes by time in VAS scales of Group II:

A arithmetic important decrease in pain levels was recorded when comparing pain levels at 24 hours showed mean VAS score 11, while at 48 hours recorded 8, and 72 hours recorded 4 ( $p<0.001$ ).

## DISCUSSION

Microbial injury is the major and the cause of postoperative pain. Therefore, a lower incidence of pain might be anticipated after the achievement of intracanal dealings built on anti- microbial strategies <sup>(15)</sup>.

In the present study, the participants that had been diagnosed with asymptomatic necrotic pulp, were included for assessment of post-operative pain. Results of the studies linking the connection between the frequency of flare-up after endodontic treatment, pain intensity and condition of the pulp (vital or necrotic) are controversial <sup>(16)</sup>. Some studies showed higher occurrence of pain in non- vibrant pulp may be owing to the existence of more germs in the complex anatomy of the apical third canal in addition to presence of periapical bone damage area <sup>(17)</sup>.

In the present study, patients with medical conditions or under antibiotic or analgesic administrations and pregnant females were excluded. Moreover, teeth associated with swelling and retreatment cases were not included so as not to be considered additional factors influencing the occurrence and strength of postoperative pain. All teeth were single rooted, necrotic and asymptomatic. More than one tooth receiving root canal treatment in the same patient cannot all be assumed to behave independently from each other, for the purposefulness such cases were excluded. As some studies concluded that, the prevalence of postoperative pain was significantly affected by preoperative pain, swelling, tooth type and systemic therapy for medical conditions <sup>(18)</sup>. Also some studies have reported a significantly higher incidence of flare ups in teeth that needed retreatment <sup>(15)</sup>.



The working length of the root canals was determined using Root ZX locator, and then confirmed radiographically. Surmont et al. 1992 and ElAyouti et al. 2002 stated that, accurate determination of the apical canal narrowing is not possible with radiography because of anatomical variations or errors in projection <sup>(19)</sup>. Therefore, some studies concluded that, location of the apical foramen using a combination of an electronic apex locator and radiographs to limit the working length is more accurate than using radiographs alone <sup>(20)</sup>.

The root canals were mechanically prepared in a crown-down approach using the “TF Adaptive” setting on Elements Motor. TF Adaptive Green ML1 file (Medium Large) size 25 taper 8%. The speed of rotation was 500 rpm and torque were 4 Ncm, and Yellow ML2 size 35 taper 4% until the file reaches working length.

Nickel-titanium rotary practices have become prevalent in latest years since they can simplify affecting actions, decrease the amount of extruded debris, while minimizing iatrogenic faults, owing to its flexibility <sup>(21,22)</sup>. Because the rotary files have considerable diminution in bacterial count with increasingly, larger instrument sizes <sup>(23)</sup>. Also complete instrumentation was performed in the first visit as studies proved that complete instrumentation is needed to obtain near optimal delivery of intracanal medication <sup>(24)</sup>.

In the present study, intracanal medicaments were applied in a paste form using the Ultracal injection system. After complete root canal instrumentation, the medication was slowly injected in an apico-coronal direction using disposable long tips with a stopper, adjusted 1 mm shorter than working length to avoid introduction of medicaments beyond root apex. Injection using a slight up and down movement was continued until the paste was seen at the canal orifice ensure complete filling of the canal. Some studies showed that in the fully prepared canal, all practices brought close to the ideal weightiness of  $\text{Ca}(\text{OH})_2$ , but the instilment system and the

lentulo spiral practice carried modestly more weight than the other techniques <sup>(24)</sup>.

The tooth was sealed using resin altered glass ionomer to ensure complete sealing and prevent leakage and washout of ICM. The second visit was after one week, as some studies proved that 7 days application of  $\text{Ca}(\text{OH})_2$  paste was able to eliminate and/or reduce the total number of bacteria to a level that gave a negative culture <sup>(25)</sup>.

Assessment of the pain intensity was carried out visual analogue scale (VAS) after 24, 48, and 72 hours. The scale was considered simpler and more reliable than the visual scale heretofore in use <sup>(26)</sup>.

The results of this study showed that, there was no arithmetic important in incidence of post-operative pain between propolis paste (group I), and  $\text{Ca}(\text{OH})_2$  paste (group II) in patient with necrotic pulp after 24, 48, 72 hours and 7 days.

Both groups recorded a significant drop in the post-operative pain score after 24 hours till the 7 days. This might be owing to the antimicrobial activity of both intracanal medicaments.

Our findings agree with a study showed, antimicrobial intracanal medication and sodium hypochlorite irrigation could stop post-operative pain <sup>(15)</sup>. Also other studies concluded that  $\text{Ca}(\text{OH})_2$  as an intracanal medication is effective in decreasing the postoperative pain and swelling in necrotic teeth compared to no dressing at all <sup>(27,28)</sup>.

While other studies counteracted our findings, Walton et al. these studies found out that there was no arithmetic important in postoperative pain between  $\text{Ca}(\text{OH})_2$  and placebo. This difference may be related to different selection of cases or methodological differences <sup>(29,30)</sup>.

On other hand our results in relation to propolis paste may be due to its flavonoid content, various esters of caffeic acid, galangin (3,5,7- trihydroxy flavone), and its bioautogram components <sup>(10)</sup>. This explanation could be supported by the results of the

invitro studies who concluded that Propolis is more active as an intracanal medication than  $\text{Ca(OH)}_2$  against *E. faecalis* <sup>(10,31)</sup>.

In contrast, the results were contradicting to other study who concluded that Propolis was less effective than  $\text{Ca(OH)}_2$  against *Candida albicans* on day 1, but equally effective after 7 days <sup>(32)</sup>.

## CONCLUSION

Propolis is an effective and safe intracanal medication that can be used to reduce post-operative pain in necrotic teeth.

## REFERENCES

6. Von Korff M, Dworkin SF, Le Resche L, Kruger A. An epidemiologic comparison of pain complaints. *Pain*. 1988; 32:173-83.
7. Gorduysus MO, Gorduysus MG. Endodontic patient profile of Hacettepe University, Faculty of Dentistry in Ankara, Turkey. *Int Dent J*. 2000; 50:274-8.
8. Wong M, Lytle WR. A comparison of anxiety levels associated with root canal therapy and oral surgery treatment. *J Endod*. 1991; 17:461-5.
9. Pak JG, White SN. Pain Prevalence and Severity before, during, and after Root Canal Treatment: A Systematic Review. *J Endod*. 2011; 37:429-438.
10. Iqbal M, Kurtz E, Kohli M. Incidence and factors related to flare-ups in a graduate endodontic programme. *Int Endod J*. 2009; 42:99-104.
11. Siqueira JF. Microbial causes of endodontic flare-ups. *Int Endod J*. 2003; 36:453-63.
12. Nair PN, Henry S, Cano V, Vera J. Microbial status of apical root canal system of human mandibular first molars with primary apical periodontitis after "one-visit" endodontic treatment. *Oral Surgery, Oral Medicine, Oral Pathology, Oral Radiology, and Endodontology*, 2005. 99:231-252.
13. Cohen S. *Cohen's Pathways of the Pulp*. Eleventh. Mosby Elsevier; 2016.
14. Balto K. Calcium hydroxide has limited effectiveness in eliminating bacteria from human root canal. *Evid Based Dent*. 2007;8(1):15-16.
15. Madhubala M, Srinivasan N, Ahamed S. Comparative evaluation of propolis and triantibiotic mixture as an intracanal medicament against enterococcus faecalis. *J Endod*. 2011;37(9):1287-1289.
16. Silica S, Kutluca S. Chemical composition and antibacterial activity of propolis collected by three different races of honeybees in the same region. *J Ethnopharmacol*. 2005;99:69-73.
17. De Souza Ferreira S, De Assis Dias B, Obregón C, Gomes C, de Araújo Pereira R. Microparticles containing propolis and metronidazole: in vitro characterization, release study and antimicrobial activity against periodontal pathogens. *Pharm Dev Technol*. 2014;19(2):173-80.
18. Neiva K, Catalfamo D, Holliday S, Wallet S, Pileggi R. Propolis decreases lipopolysaccharide-induced inflammatory mediators in pulp cells and osteoclasts. *Dent Traumatol*. 2014;30(5):362-7.
19. Ustun Y, Arslan S, Aslan T. Effects of calcium hydroxide and propolis intracanal medicaments on bond strength of resin-based endodontic sealer as assessed by push-out test. *Dent Mater J*. 2013;32(6):913-9.
20. Siqueira J, Machado A. Incidence of Postoperative Pain After Intracanal Procedures Based on an Antimicrobial Strategy. *J Endod*. 2002;28(6):457-60.
21. Sipaviciūtė E, Maneliënė R. Pain and flare-up after endodontic treatment procedures. *Stomatologija*. 2014;16(1):25-30.
22. Mathew S. Post-operative pain in endodontics: A systemic review. *J Dent Oral Hyg*. 2015;7(8):130-137.
23. Glennon J, Ng Y, Setchell D, Gulabivala K. Prevalence of and factors affecting postpreparation pain in patients undergoing two-visit root canal treatment. *Int Endod J*. 2004;37(1):29-37.
24. Hoer D, Attin T. The accuracy of electronic working length determination. *Int Endod J*. 2004;37(2):125-131.
25. Brunton P, Abdeen D, Macfarlane T. The Effect of an Apex Locator on Exposure to Radiation During Endodontic Therapy. *J Endod*. 2002;28(7):524-526.
26. Nekoofar MH, Sheykhrezae MS, Meraji N, et al. Comparison of the Effect of Root Canal Preparation by Using WaveOne and ProTaper on Postoperative Pain: A Randomized Clinical Trial. *J Endod*. 2015; 41: 575-8.
27. Ferraz CC, Gomes BP, Zaia AA, Teixeira FB, Souza-Filho FJ. Apical extrusion of debris and irrigants using two hand and three engine-driven instrumentation techniques. *International endodontic journal*, 2001. 34:354-358.



28. Alton BC, Orstavik D, Phillips C, Pettiette M, Trope M. Bacterial reduction with nickel-titanium rotary instrumentation. *J Endod.* 1998; 24:763-7.
29. Simcock R, Hicks M. Delivery of Calcium Hydroxide: Comparison of Four Filling Techniques. *J Endod.* 2006; 32(7):680-682.
30. Sjogren U, Figdor D, Spångberg L, Sundqvist G. The antimicrobial effect of calcium hydroxide as a short-term intracanal dressing. *Int Endod J.* 1991;24(3):119-25.
31. Murphy, Dermot F.; McDonald, A.; Power, C., et al. Measurement of Pain: A Comparison of the Visual Analogue with a Nonvisual Analogue Scale. *The Clinical Journal of Pain*, 1987; 3(4):197-200.
32. Ghoddusi J, Javidi M, Zarrabi M, Bagheri H, Jamileh G, Maryam J. Flare-ups incidence and severity after using calcium hydroxide as intracanal dressing. *N Y State Dent J.* 2006;72(4):24.
33. Singh R, Khatter R, Bal R, Bal C. Intracanal medications versus placebo in reducing postoperative endodontic pain-a double-blind randomized clinical trial. *Braz Dent J.* 2013;24(1):25-9.
34. Walton R, Holton I, Michelich R. Calcium hydroxide as an intracanal medication: effect on posttreatment pain. *J Endod.* 2003;29(10):627-629.
35. Ehrmann E, Messer H, Adams G. The relationship of intracanal medicaments to postoperative pain in endodontics. *Int Endod J.* 2003;36(12):868-875.
36. Saha S, Nair R, Asrani H. Comparative evaluation of propolis, metronidazole with chlorhexidine, calcium hydroxide and curcuma longa extract as intracanal medicament against *E.Faecalis*—an invitro study. *J Clin Diagnostic Res.* 2015; 9(11).
37. Chua E, Parolia A, Ahlawat P, Pau A, Amalraj F. Antifungal effectiveness of various intracanal medicaments against *Candida albicans*: an ex-vivo study. *BMC Oral Health.* 2014;14:53.



## تقييم تأثير بروبوليس مقابل تأثير هيدروكسيد الكالسيوم كأدوية داخل قناة لب العصب على ألم ما بعد حشو العصب للأسنان التي مات عصبها

محمد السيد رقية<sup>1</sup>, محمود محمد بدر<sup>2</sup>, انجي مدحت قطايا<sup>3</sup>

1. 1 قسم علاج الجذور، كلية طب الأسنان، ( أسيوط، بنين)، جامعة الأزهر، مصر

2. 2 قسم علاج الجذور، كلية طب الأسنان، جامعة المستقبل، مصر

3. 3 قسم خواص المواد السنية، المعهد القومي للبحوث، مصر

4. \*البريد الإلكتروني: MROKAYA@AZHAR.EDU.EG

### الملخص:

**الهدف:** تقييم الألم بعد استعمال بروبوليس مقابل هيدروكسيد الكالسيوم كأدوية داخل قناة لب العصب على ألم ما بعد حشو العصب للأسنان التي مات عصبها.

**الطرق والاساليب:** تم تسجيل 40 مريضاً يحتاجون إلى علاج جذور للأسنان أحادية الجذر لاستخدامهم في هذه الدراسة. وتم تقسيم المرضى المختارين إلى مجموعتين تضم كل منهما 20 مريضاً: طبقاً للمادة المستعملة داخل قناة العصب. المجموعة الأولى: عجينة بروبوليس. المجموعة الثانية: عجينة هيدروكسيد الكالسيوم. جميع الخطوات تمت تحت تأثير البنج الموضعي. وتم خديد طول قناة العصب بجهاز ROOT ZX. تم إعداد قنوات الجذر ميكانيكياً من التاج لأسفل باستخدام إبر «TF التكييفية». TF التكييفية الأخضر ML1 FILE (متوسط كبير) والأصفر ML2 حجم 35 4% حتى تص الأبرة إلى الطول المطلوب. ووضعت العلاجات المستخدمة في كل مجموعة داخل قناة العصب وتركزت لمدة أسبوع.. تم الحكم على الألم بعدها من خلال مقياس التماثل البصري (VAS) بعد 24 ساعة و 48 ساعة و 72 ساعة.

**النتائج:** أظهرت شدة الألم أنه لا يوجد فرق جدير بالملاحظة إحصائياً فيما يتعلق بالمجموعتين.

**الخلاصة:** بروبوليس هو دواء فعال وآمن داخل قنوات العصب يمكن استخدامه للحد من الألم بعد علاج جذور الأسنان التي مات عصبها.

**الكلمات المفتاحية:** بروبوليس، هيدروكسيد الكالسيوم، داخل قناة لب العصب، الألم، الأسنان التي مات عصبها

